

Sore Throat with Normal Oropharyngeal Examination

To the Editor:

A 30-year-old healthy woman presented with a 2-day history of fever and severe throat pain. She reported dysphagia and odynophagia but denied dyspnea, trismus, or sialorrhea. Amoxicillin and clarithromycin had been prescribed by her primary physician but did not relieve her symptoms. Her school-age children had complained of similar symptoms, which resolved spontaneously several days before her presentation. Her past medical history included palatine tonsillectomy 9 years previously.

Physical examination revealed vital signs within normal ranges except for a body temperature of 39.6°C. Her voice was muffled, but the airway was patent without stridor. Her oropharynx appeared normal but the anterior cervical lymph nodes were tender to palpation. The [Figure](#) shows the irregular mass at the base of the tongue on a soft tissue lateral neck radiograph. These findings are consistent with acute lingual tonsillitis. Laryngoscopy was performed following consultation with an otolaryngologist. Lingual tonsils were edematous with white exudates in the crypts. We diagnosed acute viral lingual tonsillitis based on adenovirus antigen detected in the swab. The patient recovered uneventfully on analgesics and has not experienced a recurrence.

The lingual tonsils constitute Waldeyer ring, along with the palatine, tubal, and pharyngeal (adenoid) tonsils. The tonsils consist of lymphoid tissues covering the posterior surface of the tongue behind the vallate papillae, which lie in front of the epiglottis. The tissues are likely affected by the same etiology as the palatine tonsils and can become hypertrophic or hyperplastic in response to infection, foreign bodies, and palatine tonsillectomy.^{1,2} Further, enlargement may be seen in patients with varices, congenital abnormalities (dermoid cysts, thyroglossal duct cysts, lingual thyroid gland), and benign or malignant growths of any tissues at the tongue base.^{1,3,4} Lingual tonsil swelling can cause a wide variety of signs and symptoms due to its anatomical position, including altered phonation, airway stenosis (obstructive sleep apnea, stridor, airway

compromise), interference with swallowing (dysphagia, odynophagia, globus sensation), and referred otalgia.^{1,3-6}

Acute lingual tonsillitis is an uncommon diagnosis for pharyngitis. However, given that some degree of inflammation will occur concurrently with other pharyngeal infections,⁶ it has been under-reported, probably due to the fact that this tissue can be visualized only with laryngeal mirror or laryngoscope,¹ making it difficult to evaluate. The condition should therefore be suspected in patients with a history of palatine tonsillectomy or adenoidectomy and negative oropharyngeal examinations despite the presence of a sore throat, odynophagia, or tenderness at the level of the hyoid bone.^{2-5,7} The causative organisms of lingual tonsillitis are similar to those of other pharyngitis. Among bacterial etiologies, *Streptococcus pyogenes* is the most common agent.⁶ Viral pathogens vary depending on the patient's age; children are commonly affected by adenovirus, influenza virus, parainfluenza virus, Epstein-Barr virus, human herpesvirus 4, and enteroviruses, while rhinovirus and coronavirus are more common in adults.⁸

Viral tonsillar disorder is treated with analgesics, while streptococcal tonsillitis must be treated with antibiotics. Lingual tonsillectomy may be considered for frequent recurrence.³ However, surgery must always follow avoidance of

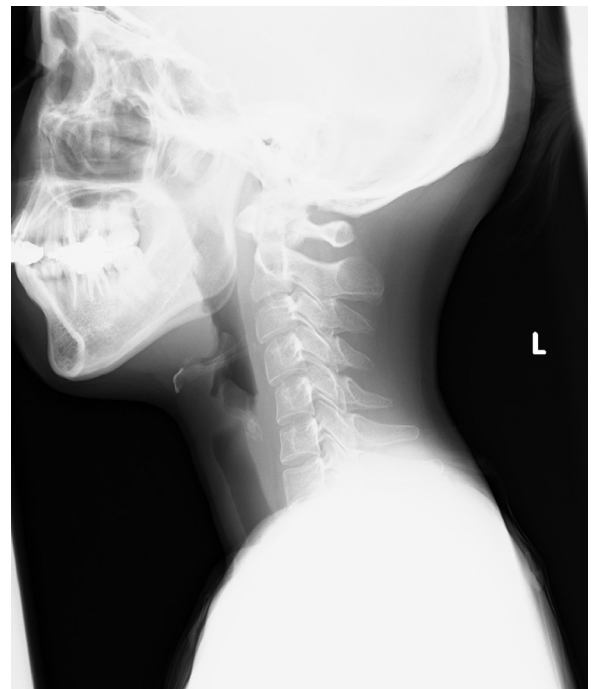


Figure The irregular mass is seen at the base of the tongue.

Funding: None.

Conflict of Interest: There are none to report.

Authorship: All authors had access to the data, and have contributed to the preparation of the manuscript.

Requests for reprints should be addressed to Hirofumi Yoshida, MD, Department of Medicine, Oregon Health and Science University, 3181 SW Sam Jackson Park Rd. Portland, OR 97239.

E-mail address: hirofumi.1623.yoshida@gmail.com

aggravating factors such as dust, tobacco, alcohol, and chemical compounds, which may reduce recurrences.^{3,4}

Hirofumi Yoshida, MD^a

Maki Kanamori, MD^b

Hideta Sakemi, MD^c

^a*Department of Medicine, Oregon Health and Science University, Portland*

^b*Department of General Internal Medicine, Kobe City Medical Center General Hospital, Kobe city, Hyogo, Japan*

^c*Rakuwakai Kyoto Medical Education Center, Rakuwakai Otowa Hospital, Kyoto city, Kyoto, Japan*

<https://doi.org/10.1016/j.amjmed.2020.06.034>

References

1. Roberge RJ, Simon M, Russell M, Decker M. Lingual tonsillitis: an unusual presentation of mononucleosis. *Am J Emerg Med* 2001;19(2):173–5.
2. Elfman LK. Lingual tonsils; a new evaluation. *Laryngoscope* 1949;59(9):1016–25.
3. Puar RK, Puar HS. Lingual tonsillitis. *South Med J* 1986;79(9):1126–8.
4. Golding-Wood DG, Whittet HB. The lingual tonsil. A neglected symptomatic structure? *J Laryngol Otol* 1989;103(10):922–5.
5. Elia JC. Lingual tonsillitis. *Ann N Y Acad Sci* 1959;82:52–6.
6. Allen DM, Hall KN, Barkman HW. Lingual tonsillitis: an uncommon cause of airway compromise responsive to epinephrine. *Am J Emerg Med* 1991;9(6):622–4.
7. Mavrinac JM, Dolan RW. Acute lingual tonsillitis. *Am J Emerg Med* 1997;15(3):308–9.
8. Windfuhr JP, Toepfner N, Steffen G, Waldfahrer F, Berner R. Clinical practice guideline: tonsillitis I. Diagnostics and nonsurgical management. *Eur Arch Otorhinolaryngol* 2016;273(4):973–87.